
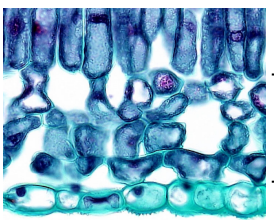
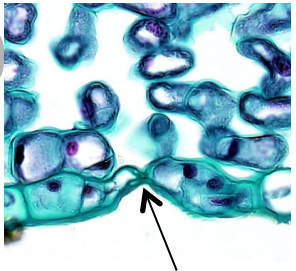
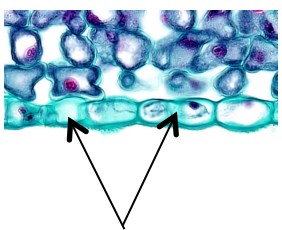
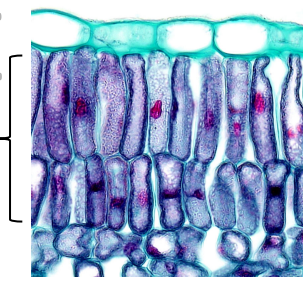
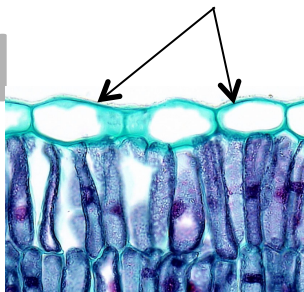
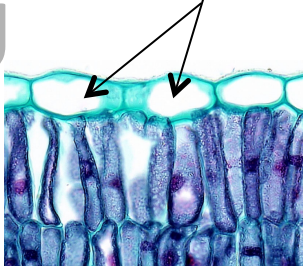
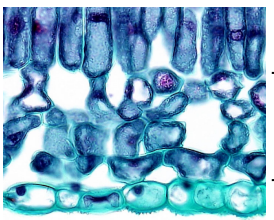
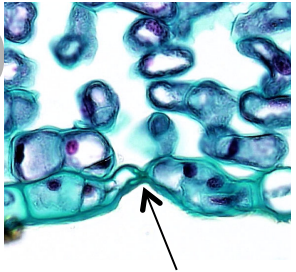
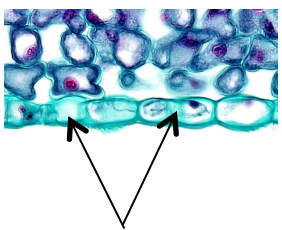
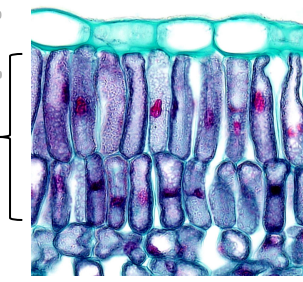


<p>Cuticula</p>	<p>U</p> 	<p>Obere Epidermis</p>	<p>L</p> 
<p>Schwamm- gewebe</p>	<p>O</p> 	<p>Spaltöffnung</p>	<p>S</p> 
<p>Untere Epidermis</p>	<p>E</p> 	<p>Palisadengewebe</p>	<p>N</p> 
<p>Cuticula</p>	<p>U</p> 	<p>Obere Epidermis</p>	<p>L</p> 
<p>Schwamm- gewebe</p>	<p>O</p> 	<p>Spaltöffnung</p>	<p>S</p> 
<p>Untere Epidermis</p>	<p>E</p> 	<p>Palisadengewebe</p>	<p>N</p> 